

## **LIDOCAINE IN VENTRICULAR TACHYCARDIA WITH HEMODYNAMICALLY UNSTABLE WHO REFUSE CARIOVERSION, IS IT THE FIRST CHOICE OR NOT?**

Yuri Savitri<sup>1</sup>, Ayu Permata Sari<sup>2</sup>, Dio Gusfanny<sup>2</sup>, Ghisca Chairiyah Ami<sup>2</sup>, Isra Namira<sup>2</sup>

<sup>1</sup>Department of Cardiology, RSUD Cut Meutia, Aceh Utara

<sup>2</sup>Faculty of Medical Student, Malikussaleh University, Lhokseumawe

Corresponding Author : [ayupermatasaribt@gmail.com](mailto:ayupermatasaribt@gmail.com)

### **Abstract**

Sudden cardiac death (SCD) is a vital public health issue, accountable for almost 50% of all cardiovascular deaths. In the last three decades, SCD was the leading cause for almost 230000 to 350000 deaths per annum in the United States. Ventricular arrhythmias account for 25% to 36% of witnessed sudden cardiac arrests (SCA) at home and 38% to 79% of witnessed SCA in public. The goals of ventricular arrhythmia management include symptom relief, improving quality of life, reducing implantable cardioverter defibrillator shocks, preventing deterioration of left ventricular function, reducing risk of arrhythmic death, and potentially improving overall survival. Based on the ACLS guideline, each tachyarrhythmia with a pulse should be given synchronized cardioversion, however, when such action could not be performed for various reasons, and showed wide QRS 0,12, intravenous or antiarrhythmia might serve as a possible treatment. If intravena antiarrhythmics are given, amiodarone may be considered. Amiodarone is also effective in preventing recurrence of monomorphic VT. Lidocaine is less effective in terminating VT than procainamide, sotalol and amiodarone. Lidocaine may be considered second-line antiarrhythmic therapy for monomorphic VT.

*Keyword: amiodarone; cardioversion; lidocaine; ventricular tachycardia*

### **Introduction**

Sudden cardiac death (SCD) is a vital public health issue, accountable for almost 50% of all cardiovascular deaths.(1) In the last three decades, SCD was the leading cause for almost 230000 to 350000 deaths per annum in the United States.(1) Ventricular arrhythmias account for 25% to 36% of witnessed sudden cardiac arrests (SCA) at home and 38% to 79% of witnessed SCA in public.(2) Ventricular arrhythmias have a broad spectrum ranging from premature ventricular contraction (PVC, also known as ventricular extrasystole or VES), ventricular tachycardia (VT), ventricular fibrillation (VF), to torsades de pointes (TDP).(3)

Ventricular tachycardia is characterized as a wide complex (QRS duration greater than 120 milliseconds) tachyarrhythmia at a heart rate greater than 100 beats per minute. It

is classified by duration as non-sustained or sustained. Non-sustained ventricular tachycardia is defined as more than 3 beats of ventricular origin at a rate greater than 100 beats per minute that lasts less than 30 seconds in duration. When the rhythm lasts longer than 30 seconds or hemodynamic instability occurs in less than 30 seconds, it is considered sustained ventricular tachycardia.(4) Further classification is made into monomorphic and polymorphic on the basis of QRS morphology.(4) The most common cause of VT is ischemic heart disease.(4) Ventricular tachycardia 48 hours after hospital presentation is associated with an increased risk of death compared to ventricular tachycardia occurring within the first 48 hours of hospital presentation.(4) .

The goals of ventricular arrhythmia management include symptom relief, improving quality of life, reducing implantable cardioverter defibrillator shocks, preventing deterioration of left ventricular function, reducing risk of arrhythmic death, and potentially improving overall survival.(5) Identification of VT should include the search for etiology, source of focus, comprehensive management, and prognosis in relation to sudden cardiac death.(6) Management in the acute setting when the hemodynamic state is stable, VT termination is done by giving intravenous drugs such as amiodarone, lidocaine, and procainamide. If medication fails, electrical cardioversion is performed, which can be started at low energy (10 joules and 50 joules). If the hemodynamic state is unstable (hypotension, shock, angina, heart failure, and symptoms of cerebral hypoperfusion) then the first option is electrical cardioversion.

### **Case Report**

A 67-years-old male patient, domiciled in Blang Teurakan, North Aceh, the patient was brought from Arun Hospital and admitted to emergency department of Cut Mutia hospital at 21.00 pm on March 12<sup>st</sup>, 2022. Patient was admitted to the hospital with complaints dyspnea. The patient also complains of chest feel heavy, dyspnea is felt suddenly when the patient is inactive and gets worse during activities, the shortness decreases when the patient rests. Complaints felt by the patient for the first time since the age of 55 years. The patient also complained of a cough with phlegm that had been felt since about 2 years ago. The patient has a history of lung disease and was treated at the Kesrem Hospital in 2014. The patient has a habit of eating coconut milk, fatty, oily foods. Patient is a smoker.

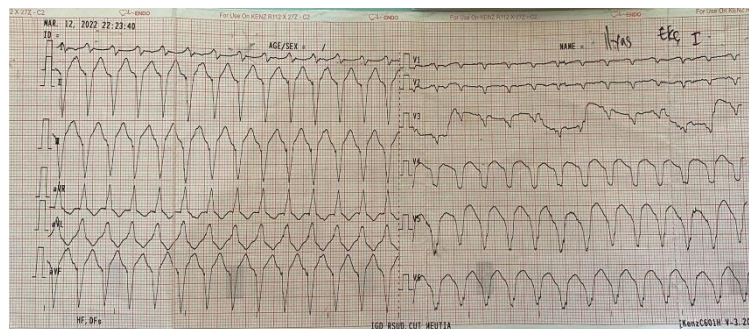
Physical examination before treatment was obtained the patient looked restless, weakness and breathless, BP: 90/70 mmHg, HR: 165x/m, RR: 28x/m, T: 36,5 °C, SpO<sub>2</sub>: 99%. Chest examination show breath sounds were rhonki. In this case on physical

examination showing tachycardia. After treatment, physical examination was obtained BP: 130/80 mmHg, HR: 62x/m, RR: 29x/m T:36,5 °C, SpO<sub>2</sub> 88% (on nasal canule). Chest examination show breath sounds were rhonki.

The result of laboratory on March, 12<sup>st</sup> 2022, there were hemoglobin with 12.90 g/dl, leucocyte with 9.73 ribu/uL, thrombocyte with 170 ribu/uL and blood glucose with 176 mg/dl, and then the result of laboratory on March, 13<sup>rd</sup> 2022, there were hemoglobin with 12.07 g/dl, leucocyte with 7.62 ribu/uL, thrombocyte with 152 ribu/uL and blood glucose with 176 mg/dl electrolyte with Na 122 mmol/L, K 3.2 mmol/L, Cl 104 mmol/L, and Ca 0,32 mmol/L.

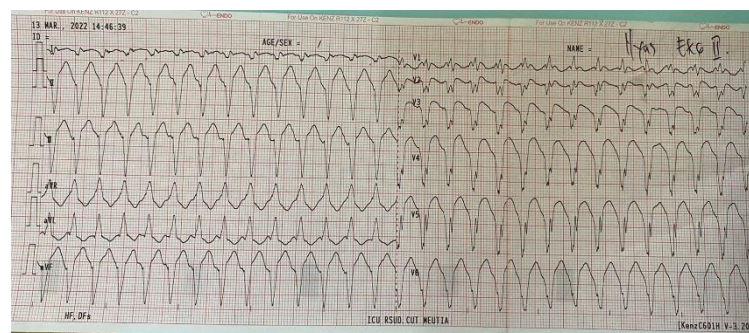
with troponin

Coagulation  
<0.01 ng/mL.



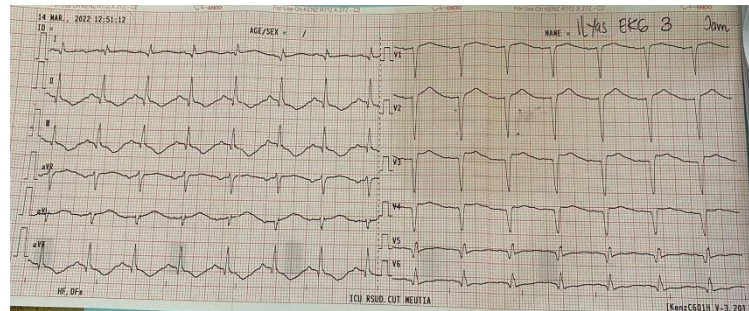
**Figure 1. ECG Findings**

The electrocardiogram examination showed that ventricular beats with rate 214 bpm, P-waves are visible in Lead II but they do not any relation to the QRS complexes. This situation is referred to as “AV dissociation” and indicates that atrial and ventricular activity and independent, wide QRS complexes (QRS duration 0,32 s), all QRS complexes display same morphology: Monomorphic VT.



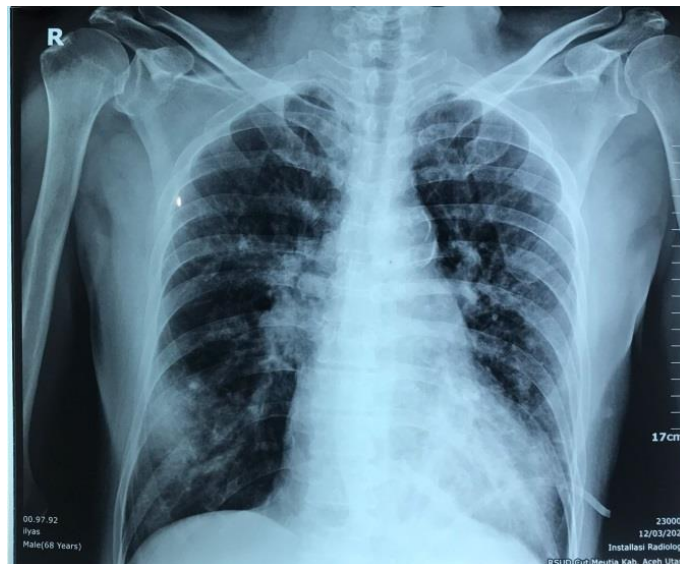
**Figure 2. ECG Findings**

The second electrocardiogram examination still showed monomorphic VT with a new right bundle branch block in lead V1 and V2.



**Figure 3. ECG Findings**

The third electrocardiogram examination showed QS pattern with ST segment elevation at lead V1 (1mm) V2 (2 mm), V3 (2 mm), V4 (1 mm). The conclusion was ST-elevation myocardial infarction anteroseptal late onset.



**Figure 5. X-Ray Findings**

### **COR**

- CTR >50%
- Aortic segment was normal
- Pulmonary was not prominent
- The apex of the heart is shifted laterocaudally.
- The waist is flat, the left main bronchus is elevated.

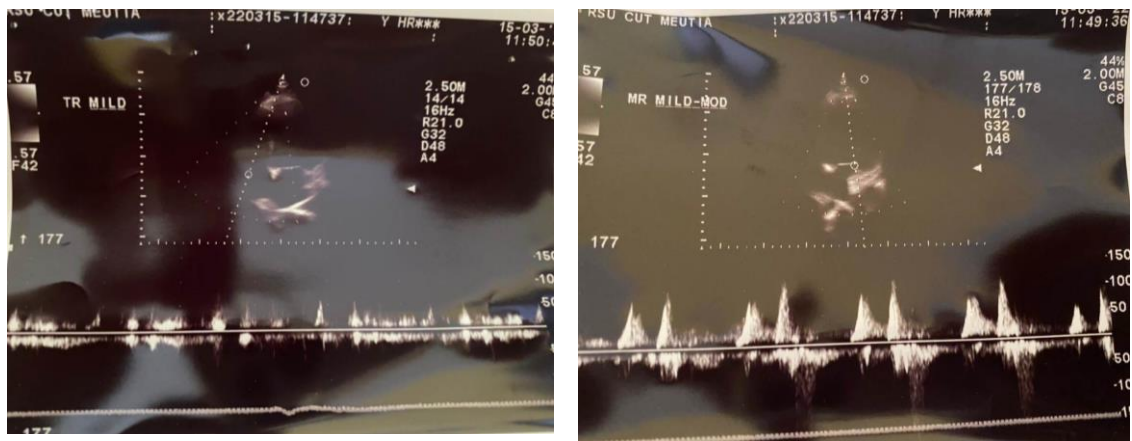
### **PULMO**

- Vascular pattern looks increased
- Spots appear on both lung fields

- Consolidation is seen on the right paracardial

## Result

- Cardiomegaly (LV,LA)
- Overview of suspected underlying TB.



**Figure 3. Echocardiography Findings**

Echocardiography examination showed that the MR mild-moderate, TR mild and LV LA Dilated with EF was 31%.

The patient was given treatment in Cut Mutia General Hospital. We administrate O2 3-5 LPM, Nacl 3% 10 gtt/i, injection of furosemide 1cc/h injection of arixtra /24h, injection of dobutamine 5 cc/h, drip amiodarone 4 amp in dextrose 5% over four hours. Lidocaine was given by slow bolus (5.2 cc single dose) and maintenance dose 0.05 cc/m over 15 minutes. Aptor 1x100 mg, CPG 1x75 mg, NKR 2x2.5 mg, lansoprazole 2x30mg and simvastatin 1x20mg.

## Discussion

Ventricular tachycardia is a heart rhythm problem (arrhythmia) caused by irregular electrical signals in the lower chambers of the heart (ventricles). This condition may also be called V-tach or VT. In ventricular tachycardia, a cardiac rhythm with a rate >100 beats per minute and a QRS width >120 milliseconds (ms). Treatment for ventricular tachycardia may include medication, a shock to the heart (cardioversion), catheter procedures or surgery to slow the fast heart rate and reset the heart rhythm. This activity reviews the evaluation and management of ventricular tachycardia and enhance outcomes for affected patients (7,8).

Patient was admitted to the hospital with complaints dyspnea, that was felt a few hours before the patient going to hospital. Dyspnea is felt suddenly, worsens during activity, sometimes patient feels chest so heavy. The patient also complained of a cough with phlegm since 2 years ago and heavy at night. Past medical history such hypertension and diabetes mellitus are denied, but has a history of lung disease. On physical examination, he had cold sweats, weakness and breath sounds were rhonki, blood pressure of 90/70 mmHg, HR: 125 bpm, RR: 28x/m, T: 36,0C, SpO2 99%.

In this case on laboratory examination on March 13rd, 2022 results normal cardiac troponin <0,1 ng/mL. Serum cardiac biomarkers (creatinine kinase [CK], CK-MB, cardiac specific troponins, myoglobin) are useful for confirming the diagnosis of MI and estimating infarct size. If cardiac biomarkers do not increase significantly, the diagnosis is unstable angina pectoris. In acute coronary syndrome, the value of threshold for abnormally elevated cardiac biomarkers is several units above upper limits of normal (9).

ECG in emergency department before treatment showed that ventricular beats with rate 214 bpm, P-waves are visible in Lead II but they do not any relation to the QRS complexes. This situation is referred to as "AV dissociation" and indicates that atrial and ventricular activity are independent, wide QRS complexes (QRS duration 0,32 s), all QRS complexes display the same morphology. This patient's wide QRS complex represents a VT, according to Brugada algorithm and showed monomorphic VT. In structural heart disease monomorphic ventricular tachycardia is typically caused by re-entry. Coronary artery disease is by far the most common cause of VT and the mechanism is mostly re-entry. Re-entry occurs when there is a central block ahead of the depolarizing impulse and the cells surrounding the block has varying conductivity. In ischemic heart disease, the central block is typically ischemic/necrotic myocardium (which do not conduct any impulses) while the surrounding cells have dysfunctional conduction due to ischemia (10,11)(12).

X-ray examination showed the presence of cardiomegaly. That means cardiomegaly occurs when the heart muscle pumps blood harder than usual, causing thickening of the heart muscle, so the heart becomes larger in size.

Based on the results of the fractional ejection examination in this patient, the result was 31% which indicated this patient had congestive heart failure (CHF). In CHF, structural changes including chamber dilatation, and alteration of the cellular ionic currents, the receptors and the gap junction, provide adequate substrates for the genesis of arrhythmias (14).

The patient was admitted to intensive care with amiodarone drip 600mg/12ml over 4 hours. Electrical cardioversion was planned, but the patient refused to do and the patient treated with standard acute coronary syndrome protocol therapy. On the second day of admission, still showed monomorphic ventricular tachycardia with a new right bundle branch block. Amiodarone was given by bolus (300 mg/6 ml), lidocaine was given by slow bolus (5,2 cc (single dose)) and maintenance dose 0,05 cc/minute over 15 minutes. Continuous amiodarone drip 600mg/12ml over 4 hours.

The rhythm after bolus and infusion of lidocaine was converted to sinus after 22 hours later and ecg showed QS pattern with ST Segment elevation at lead V1 (1mm) V2 (2 mm), V3 (2 mm), V4 (1 mm). The conclusion was ST-elevation myocardial infarction anteroseptal late onset. STE in lead V1-V4 has been associated with infarct-related occlusion proximal to the first diagonal branch of the left anterior descending (LAD) coronary artery (13).

Based on the ACLS guideline, each tachyarrhythmia with a pulse should be given synchronized cardioversion, however, when such action could not be performed for various reasons, and showed wide QRS 0,12, intravenous or antiarrhythmia might serve as a possible treatment (15). If intravenous antiarrhythmics are given, amiodarone may be considered. Amiodarone is also effective in preventing recurrence of monomorphic VT or treating refractory ventricular arrhythmias in patients with CAD and poor ventricular function. Amiodarone is given 150 mg IV over 10 minutes; the dose may be repeated if necessary with a maximum dose of 2.2 g IV per 24 hours. Higher doses (300 mg) cause an increased frequency of hypotension, although some reports suggest hypotension due to vasoactive solvents. Lidocaine is less effective in terminating VT than procainamide, sotalol and amiodarone. Lidocaine may be considered second-line antiarrhythmic therapy for monomorphic VT. Lidocaine can be given at a dose of 1-1.5 mg/kg IV bolus. Therapy can be continued continuously using a syringe/infusion pump at a dose of 0.05 mg/kg/minute. One randomized comparison trial found that procainamide (10 mg/kg) was superior to lidocaine (1.5 mg/kg) for the termination of stable monomorphic VT (16).

Lidocaine is the first-line therapy in stable VT and is useful for VT due to myocardial infarction. Lidocaine is a class IB antiarrhythmic which is a sodium channel blocker and shortens the refractory period. In the acute period of VT due to myocardial infarction, lidocaine results in better survival than amiodarone. Amiodarone may be given to hemodynamically unstable VT. Amiodarone is the most effective antiarrhythmic, but as many 20% of patients repeat. Amiodarone has a negative vasodilator and inotropic effect, so it can

stabilize hemodynamics. The onset action of amiodarone is slower than lidocaine and procainamide (17).

Arrhythmia in the form of ventricular tachycardia in this patient can be caused by an association of abnormalities in the heart, including: coronary circulation disorders (CAD) in which the use of coronary arteries to supply oxygen to heart muscle cells. If there is a coronary circulation disorder, it will result in ischemia and even necrosis of heart muscle cells, resulting in impaired impulse conduction. After five days of follow-up, the patient remained clinically stable and was discharged from the hospital.

### **Conclusion**

Ventricular tachycardia is a heart rhythm problem (arrhythmia) caused by irregular electrical signals in the lower chambers of the heart (ventricles). This condition may also be called V-tach or VT. In ventricular tachycardia, a cardiac rhythm with a rate  $>100$  beats per minute and a QRS width  $>120$  milliseconds (ms). Treatment for ventricular tachycardia may include medication, a shock to the heart (cardioversion), catheter procedures or surgery to slow the fast heart rate and reset the heart rhythm. This activity reviews the evaluation and management of ventricular tachycardia and enhance outcomes for affected patients. Lidocaine is the first-line therapy in stable VT and is useful for VT due to myocardial infarction. Lidocaine is a class IB antiarrhythmic which is a sodium channel blocker and shortens the refractory period. In the acute period of VT due to myocardial infarction, lidocaine results in better survival than amiodarone. Amiodarone may be given to hemodynamically unstable VT. Amiodarone is the most effective antiarrhythmic, but as many 20% of patients repeat. Amiodarone has a negative vasodilator an inotropic effect, so it can stabilize hemodynamics. The onset action of amiodarone is slower than lidocaine and procainamide. Arrhythmia in the form of ventricular tachycardia in this patient can be caused by an association of abnormalities in the heart, including: coronary circulation disorders (CAD) in which the use of coronary arteries to supply oxygen to heart muscle cells. If there is a coronary circulation disorder, it will result in ischemia and even necrosis of heart muscle cells, resulting in impaired impulse conduction. After five days of follow-up, the patient remained clinically stable and was discharged from the hospital.



## References

1. Al-Khatib SM, Stevenson WG, Ackerman MJ, Bryant WJ, Callans DJ, Curtis AB, Deal BJ, Dickfeld T, Field ME, Fonarow GC, Gillis AM, Granger CB, Hammill SC, Hlatky MA, Joglar JA, Kay GN, Matlock DD, Myerburg RJ PR. 2017 AHA/ACC/HRS Guideline for Management of Patients With Ventricular Arrhythmias and the Prevention of Sudden Cardiac Death: Executive Summary: A Report of the American College of Cardiology/American Heart Association Task Force on Clinical Practice Guid. *Circulation*. 2018;138(13):210–71.
2. Spartalis M, Spartalis E, Tzatzaki E, Tsilimigras DI, Moris D, Kontogiannis C, et al. Novel approaches for the treatment of ventricular tachycardia. *World J Cardiol*. 2017;10(7):52–9.
3. Yamin M, Harun S. Buku Ajar Ilmu Penyakit Dalam: Aritmia Ventrikel. VI. Interna Publishing; 2015. 1387 p.
4. Yamin M. Penyakit Kardiovaskular (PKV): Takikardia Ventrikel Apa yang Harus Diwaspadai? IV. Badan Penerbit Fakultas Kedokteran Universitas Indonesia; 2016. 411 p.
5. Foth C, Gangwani MK AH. Ventricular Tachycardia. Treasure Island (FL): StatPearls Publishing; 2021. 2-4 p.
6. Gopinathannair R, Batul SA, Olshansky B, Fisher JD. Recent advances in the management of ventricular tachyarrhythmias. *F1000Research*. 2017;6(0).
7. Garner JB, Miller JM. Clinical Arrhythmias Wide Complex Tachycardia – Ventricular Tachycardia or Not Ventricular Tachycardia , That Remains the Question Clinical Arrhythmias. *Arrhythmia Electrophysiol Rev*. 2013;23–9.
8. I.Rilantono L. Penyakit Kardiovaskular (PKV). VI. Jakarta: Fakultas Kedokteran Universitas Indonesia; 2016. 411-417 p.
9. Perki. Pedoman Tata laksana Sindrom Koroner Akut. Jakarta: Indonesian Heart Association; 2018.
10. Thaler MS. Aritmia. In: Novrianti dr. A, Ginawati D, editors. *The Only EKG Book You'll Ever Need*. 7th ed. Jakarta: EGC; 2015. p. 117–8.
11. Rawshani D. Ventricular tachycardia (VT): ECG criteria, causes, classification, treatment (management). In: *Clinical ECG Interpretation*. 2nd ed. ECG & Echocardiography Education; 2021.
12. Deshmukhsamuel DJ, May JAM, Kashou AH, Noseworthy PA, Desimone C V. Wide Complex Tachycardia Differentiation: A Reappraisal of the State of the Art. *Am Hear Assoc*. 2020;9.
13. Dharma S. Cara Mudah Membaca EKG. Jakarta: EGC; 2015. 23 p.
14. Gagal Jantung. In: Buku Ajar Ilmu Penyakit Dalam. VI. Interna Publishing; 2015. p. 1134–6.
15. Tachycardia With a Pulse Algorithm. ACLS Training Center; 2021 p. 2940.
16. Perki, IDI. ACLS Indonesia. In: Buku Ajar Kursus Bantuan Hidup Jantung Lanjut. Jakarta; 2020. p. 67–9.
17. Leni Agnes Siagian. Tatalaksana Takikardia Ventrikel. *Contin Med Educ*. 2018;45(9):10–2.

